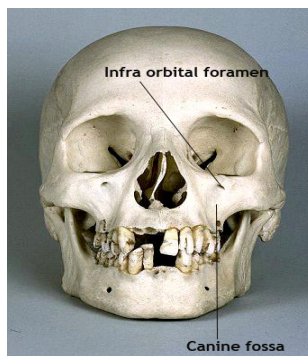


Anatomy of Paranasal sinuses



Balasubramanian Thiagarajan

Anatomy of Paranasal sinuses

Abstract:

Paranasal sinuses are air filled hollow sacs seen around the skull bone. These sacs precisely surround the nasal cavity. There are four paired sinuses surrounding the nasal cavity. This article attempts to trace the history of anatomy of paranasal sinuses from early 16th century till date. The advent of nasal endoscopes have added another dimension to the anatomical study of paranasal sinuses. The entire subject of anatomy of paranasal sinuses has been rewritten after endoscopes were started to be used commonly.

Introduction:

Precise understanding of anatomy of paranasal sinuses is an important prerequisite in avoiding complications during endoscopic sinus surgery. Common complications following endoscopic sinus surgery are caused by inadequate understanding of the highly complex and variable anatomy of paranasal sinuses.

History:

In ancient times nasal sinuses were considered to be a system of hollow spaces through which secretions from brain drained¹. Leonardo Davinci in 1489 was the first to prepare detailed anatomical drawings of paranasal sinuses which is still considered to be accurate till date². This drawing became accessible to the scientific community only as late as 1901.



Portrait of Leonardo Davinci

Davinci described maxillary sinus as the cavity within the bone that supports the cheek. This is still an undisputed fact. This description comes from a versatile artist cum scientist. Davicini was actually an unique combination of an artist cum scientist. His scientific descriptions were backed by his ability to draw astounding images.

Literature on the anatomy of paranasal sinuses dates back to 130 AD. Galen during this period documented the presence of porosities around skull bones. Highmore in 1651 gave an accurate description of maxillary sinus. Maxillary sinus is still known as antrum of Highmore in honour of his description³. It was during early 19th century Zukerkandl came out with detailed anatomical description of paranasal sinuses. He was also able to demonstrate the various pathologies affecting these air filled sacs. It was C. V. Schneider of Germany who suggested that mucous was not a product of brain but on the contrary was secreted by the lining mucosa of paranasal sinuses. In his honor the nasal mucous membrane is known as schneiderian membrane.

The advent of CT scan has thrown a lot of light as far as paranasal sinus anatomy is concerned. It should also be pointed out even after the advent of advanced imaging techniques we have not added much to the descriptions already made by Onodi, Grunwald and Zuckerkandl. This is an apt testimony to the ability of our forefathers⁴.

Definition:

Paranasal sinuses are air filled sacs found in the skull bone. These sacs infact surround the nasal cavity. There are 4 paired sinuses. They are:

1. Maxillary sinuses
2. Frontal sinuses
3. Ethmoidal sinuses
4. Sphenoidal sinuses

Each of these sinuses are named according to the facial bones

Maxillary sinus (Antrum of Highmore): These paired sinuses lie under the cheek. It is the largest of the group of para nasal sinuses. The capacity of the maxillary sinus is roughly 1 fluid ounce (30ml). It is more or less shaped like a pyramid. This is the first sinus to develop

Base (medial wall): The base of the pyramid corresponds to the lateral nasal wall. This wall has its convexity facing the sinus. The central portion of the base is very thin, and in some areas could even be membranous. The natural ostium of this sinus is present in this wall. It is present more towards the roof of the sinus cavity than its base.

Anterior: Wall corresponds to the facial surface of the superior maxilla. Over the canine fossa it is only 2mm in thickness. It is through this canine fossa area that maxillary antrum is entered during Caldwell Luc surgery.

Boundaries of Canine fossa:

Inferior: Bounded by the alveolar ridge

Laterally: Bounded by the canine eminence which is caused by the canine tooth.

Superior: Infra orbital foramen

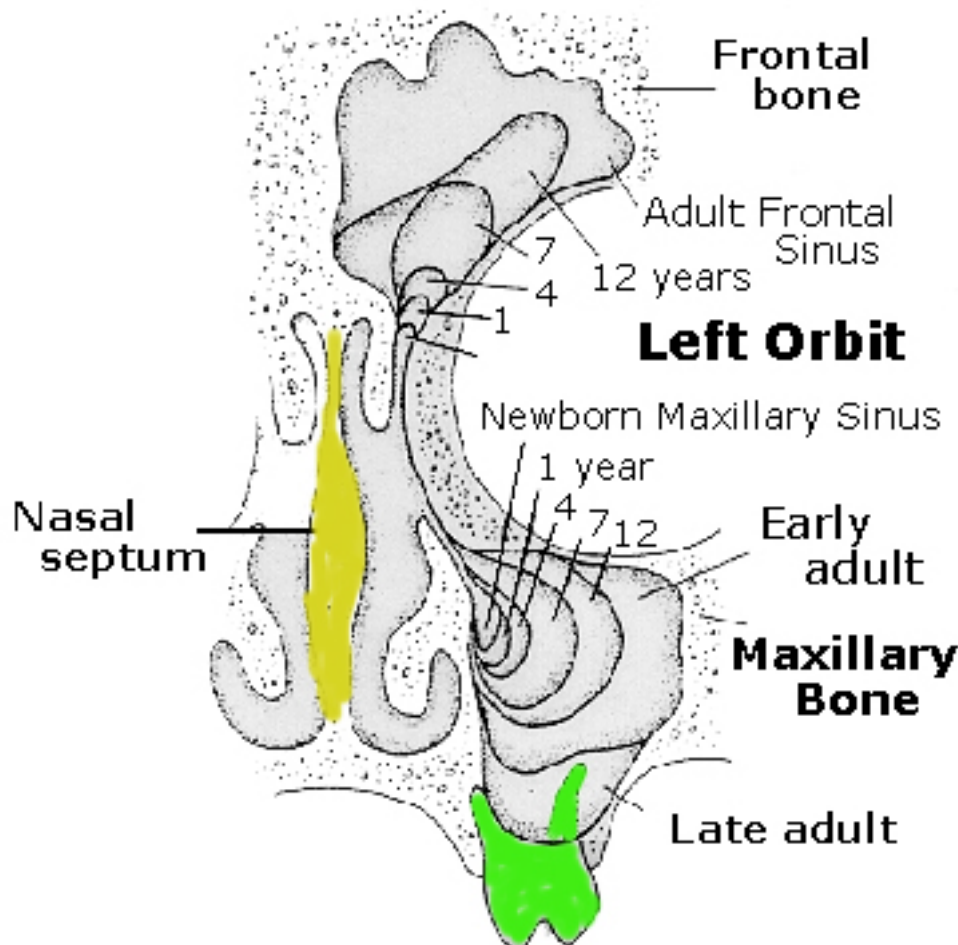
Medial: Pyriform aperture. This does not contain bone, but is lined by middle meatus mucosa, a layer of connective tissue and the sinus mucosa⁷.

Posterior wall: of maxillary sinus is also known as temporal surface. It is very thick and is formed by the body of the superior portion of the maxilla.

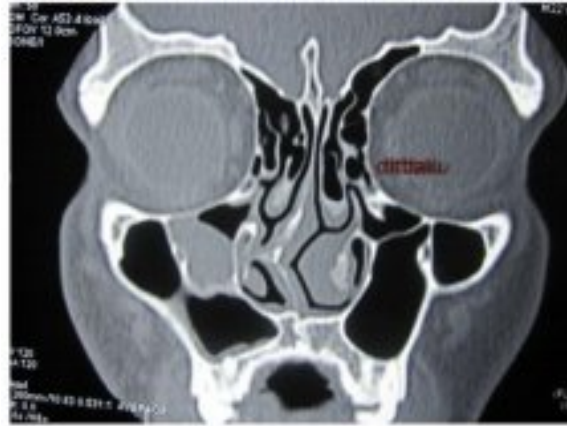Roof: of the sinus is formed by its thin orbital wall which is traversed by the infra orbital foramen containing the infra orbital vessels and nerves. This wall is very fragile and any disease process involving the maxilla is likely to affect the orbit through this wall. This wall is further thinned out where the infra orbital canal is present.

Floor: is formed alveolar process of the maxilla and the hard palate. The roots of the first and second molar reach up to the floor of the maxillary sinus. In children the floor lies at the same level as that of the nasal cavity. In adults it lies 5 - 10 mm below the nasal cavity. It is just separated from the floor of the sinus by a thin lamella of bone. This lamella may be dehiscent commonly. Dental infections involving the 1st and 2nd molars may involve the maxillary sinus through this thin lamella of bone.

The most common anatomical variation is the presence of infraorbital cell (Haller cell). These are pneumatized anterior ethmoidal cells projecting along the floor of the orbit. These cells when infected can compromise drainage of maxillary sinus. If this cell is present removing it during surgery will allow precise identification of floor of the orbit and the posterior wall of maxillary sinus. This is rather useful when anatomy is rather distorted due to disease.



Embryology of paranasal sinuses



CT Scan coronal showing Haller cell

Paranasal sinuses develop from ridges and furrows in the lateral nasal wall. This development begins as early as 8th week of intrauterine life and proceeds well into early adulthood⁵.

The maxillary sinus has biphasic growth. The first phase of growth occurs during the first 3 years of life while the second phase occurs between 7 - 18 years.

Ethmoid sinus:

The ethmoid sinus is referred to as ethmoidal labyrinth because of the complexity of anatomy, its honey combed appearance and presence of intricate pathways and blind alleys. It is situated in the anterior skull base. It is located lateral to the olfactory cleft and olfactory fossa. It is made up of complex bony labyrinth of thin walled cells. A few ethmoid cells may be present at birth. This number could easily go beyond 15 in adults. The common infections affecting the pediatric age group occur in these sinuses. In adults 6 - 10 ethmoid cells may be present. It is the most compartmentalized of all paranasal sinuses. The width of ethmoid increases from anterior to posterior because of the cone like structure of orbit.

Boundaries:

Lateral wall: is formed by the orbital plate of the ethmoid otherwise known as the lamina papyracea. This is a thin lamina of bone separating the orbit from the ethmoidal air cells. This wall could be dehiscent (normal variant). Infections involving the ethmoid air cells may spread to the orbit through this wall.

Roof: is formed by the frontal bone anteriorly, this area is known as fovea ethmoidalis⁸, and by the face of sphenoid and orbital process of palatine bone posteriorly. The frontal bone component of the ethmoidal roof is very thick. The transition of this thick fovea to the thin portion of roof of ethmoid medially is very weak. This is in fact the weakest portion of this area and is prone to

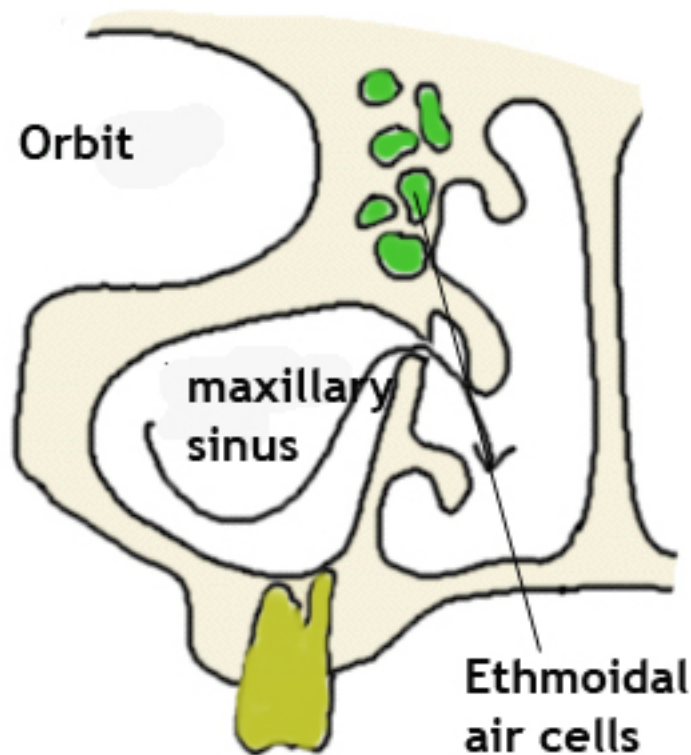
injuries during surgery leading on to csf leak. The anterior and posterior ethmoidal arteries run along the roof of the ethmoid from lateral to medial. These arteries are branches of ophthalmic artery.

The ethmoidal cells increase in size from above downwards, and from before backwards.

The cells of the ethmoid sinus are divided into two groups, the anterior and posterior group. The anterior ethmoidal cells drain into the infundibulum of the middle meatus while the posterior ethmoid cells drain into the superior meatus. The anatomy of the ethmoidal cells are highly variable, sometimes the middle turbinate may contain an air cell known as the concha bullosa. An enlarged concha bullosa may impede drainage from the middle meatus. Another common anatomical variation is the presence of agger nasi air cell. This is a large ethmoidal air cell present just anterior to the antero superior attachment of the middle turbinate. Since these cells lie in close proximity to the frontal recess area, they could impede ventilation and drainage of the frontal sinus. These agger nasi cells are commonly involved in the pathogenesis of the formation of frontal mucocele.

Obstruction to the frontal sinus drainage by the presence of a large agger nasi cell may cause secretions within the frontal sinus to be dammed inside. Accumulation of mucoid secretions cause enlargement of frontal sinus. At first the frontal sinus enlarges in size by expansion of its bony walls. At a later stage bone erosion can also occur. commonly the posterior table of the frontal sinus is eroded. The anterior table also can be eroded in rare cases.

Haller cells are ethmoidal air cells belonging to the anterior ethmoidal group. These cells are also known as the infra orbital cells. Enlargement of these cells can impede the maxillary sinus drainage. Another variation is the extension of the posterior group of ethmoidal air cells supero lateral to the sphenoid sinus. These cells are known as onodi cells. These cells lie perilously close to the optic nerve making them at risk during fess surgeries.



Diagrammatic representation of maxillary and ethmoidal sinuses

Simplified anatomy of ethmoidal sinus:

The entire anatomy of ethmoid sinus can be simplified if it is considered to be 5 obliquely oriented parallel lamellae. These lamellae are embryologically known to be derived from the ridges in the lateral nasal wall of the foetus known as ethmoturbinals. These lamellae are relatively constant and are easy to identify during surgery.

First Lamella:

This is the anterior most lamella. Anatomically this corresponds to the uncinate process. Embryologically this represents the basal lamella of the first ethmoturbinal. This lamella is encountered by the surgeon first. It should be removed before other portions of the ethmoid sinus and its drainage system becomes visible.

Second Lamella:

This corresponds to Bulla ethmoidalis. This is the largest and most constant of the anterior ethmoidal air cells⁹. This cell was identified by Zuckerkandl. This is usually round in shape with thin walls. It extends from the lamina papyraea laterally and bulges into middle meatus medially. Rarely this air cell is not pneumatized resulting in a bony projection arising from lamina papyracea. This projection is known as torus lateralis.

Third Lamella:

This is the most important of all lamella. This happens to be the ground lamella / Basal Lamella of middle turbinate. This lamella separates anterior ethmoidal air cells from posterior ethmoidal ones. This division is mandatory for the simple reason that anterior ethmoid air cells drain via the middle meatus and posterior ethmoidal air cells drain via sphenoethmoidal recess. From surgeon's point of view it is the limit for anterior ethmoidectomy. This lamella stabilizes the middle turbinate.

Fourth Lamella:

This happens to be the basal lamella of superior turbinate.

Fifth Lamella:

This is the basal lamella of supreme turbinate.

Anterior ethmoidal air cells:

Agger Nasi:

This is the anterior most of all ethmoidal air cells. The term Agger in Latin means Mound/Eminence. Endoscopically this cell is visualised as a prominence anterior to the insertion of middle turbinate. Rarely this pneumatization can involve the antero superior portion of uncinate process. Embryologically this cell is a pneumatization of superior remnant of first ethmoturbinal whorl present in the lateral wall of nasal cavity. Identification of agger nasi holds the key to access to frontal recess area. Pneumatization of agger nasi can have an impact on uncinate process insertion and patency of frontal recess area.

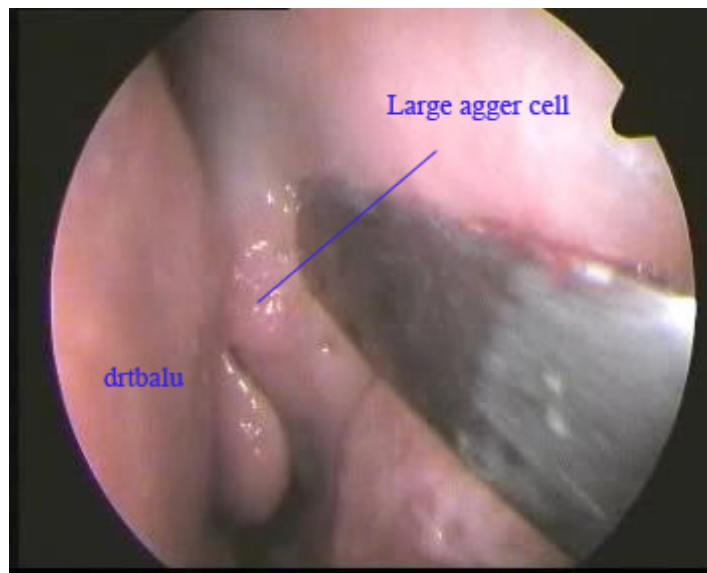
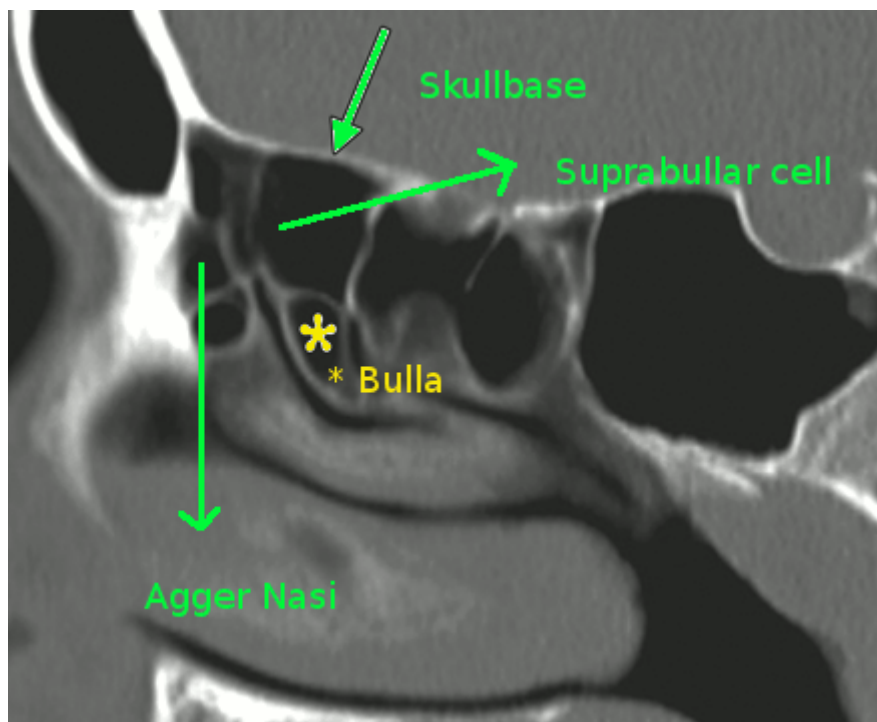


Figure showing a large aggar nasi air cell



Sagittal view of CT nose and pns showing large agger nasi cell and supra bullar cell. Note frontal recess is bounded anteriorly by agger nasi cell and posteriorly by suprabullar air cell

Supraorbital ethmoidal cells:

These cells are also known as suprabullar cells. These cells belong to the anterior ethmoidal group. These cells originate from immediately behind the frontal recess and extends over the orbit due to pneumatization of orbital plate of frontal bone. This in association with large agger nasi can compromise frontal sinus drainage pathway. During surgery this air cell can be mistaken as frontal sinus. On transillumination with telescope the light will be seen in the inner canthal area as compared to that of supra orbital area which will be transilluminated by frontal sinus¹¹.

Middle turbinate pneumatization:

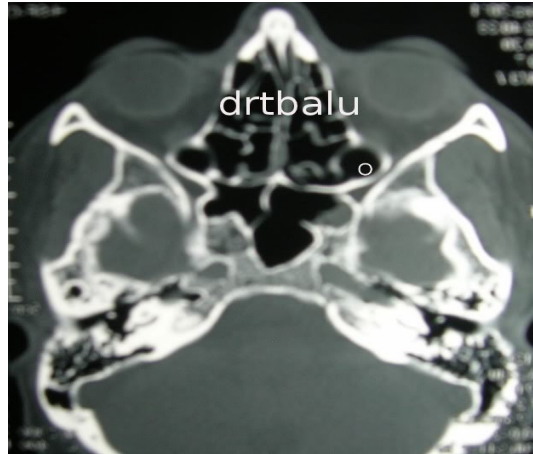
Sometimes middle turbinate may be pneumatized. A pneumatized middle turbinate is known as concha bullosa. Pneumatization of concha bullosa usually arises from frontal recess area / agger nasi air cells. This should be considered as a normal variant and does not require surgery. Ofcourse extensive pneumatization may narrow osteomeatal complex impeding sinus drainage. This condition requires surgical intervention¹⁰.

Interlamellar cell of Grunwald:

This cell is pneumatization of vertical portion / lamella of middle turbinate. This pneumatization arises from the superior meatus. This air cell was first described by Grunwald⁸.

Onodi Cell:

This cell is also known as sphenoethmoidal cell. This cell is christened after Adolf Onodi¹² of Budapest who studied the relationship of ethmoid air cells in relation to optic nerve. These cells belong to posterior ethmoid group. Onodi cells extend superiorly and laterally to the sphenoid sinus. Its pneumatization can reach up to the clinoid process. This cell is related to optic nerve in its lateral wall. If this cell is large carotid artery could be seen bulging from its posterior wall. Any attempt to open the sphenoid sinus through this cell is fraught with dangerous complications like injury to optic nerve / internal carotid artery. Pre op CT scan is the best way to identify this condition. "Forewarned is forearmed".



Axial CT nose and sinuses showing Onodi cell marked as o

Frontal sinus:

Among the para nasal sinuses this sinus shows the maximum variations. Infact variations are so immense that it can safely be stated that frontal sinuses are unique in each and every individual. It may be absent in 5 % of individuals. It is more or less shaped like a L. Drainage channel of frontal sinus is highly variable.

Posterior wall: corresponds to the anterior wall of the anterior cranial fossa.

Floor: is formed by the upper part of the orbits.

Frontal sinus appear very late in life. Infact they are not seen in skull films before the age of 6.

The sinus drains into the anterior part of the middle meatus through the fronto nasal duct.

Frontal outflow tract shows conglomeratization of air cells.

Types of frontal sinus air cells include:

I – Type I frontal cell (a single air cell above agger nasi)

II – Type II frontal cell (a series of air cells above agger nasi but below the orbital roof)

III – Type III frontal cell (this cell extends into the frontal sinus but is contiguous with agger nasi cell)

IV – Type IV frontal cell lies completely within the frontal sinus

Sphenoid sinus:

Is located in the skull base at the junction of the anterior and middle cranial fossa. Pneumatization of sphenoid starts during the 4th year of childhood and gets completed by the 17th year. The sphenoid

sinuses vary in size and may be asymmetric. Each of these sinuses are separated by an intersinus septum which may not be in the midline. Because of asymmetry the intersinus septum could be deviated to one side. This intersinus septum could attach posteriorly to the bony carotid canal. Care should be taken while removing this septum without injuring carotid artery canal. It is prudent to use true cut forceps to remove the intersinus septum. Pneumatization of sphenoid sinus can also involve anterior clinoid process, posterior clinoid process and posterior end of nasal septum.

They drain through the superior meatus via a small ostium about 4mm in diameter located disadvantageously 20mm above the sinus floor.

This sinus is related to several important vital structures. They are:

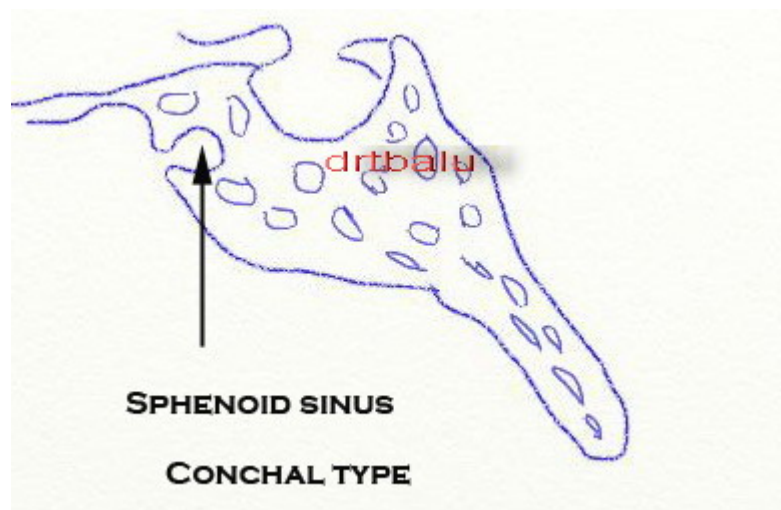
1. Pituitary gland lies above the sphenoid sinus.
2. Optic nerve and internal carotid arteries traverse its lateral wall.
3. The nerve of pterygoid canal lie in the floor of the sinus.

Hence infections of sphenoid sinus may involve the optic nerve if the canal of the optic nerve is dehiscant.

Types of sphenoidal sinuses depending on extent of pneumatization:

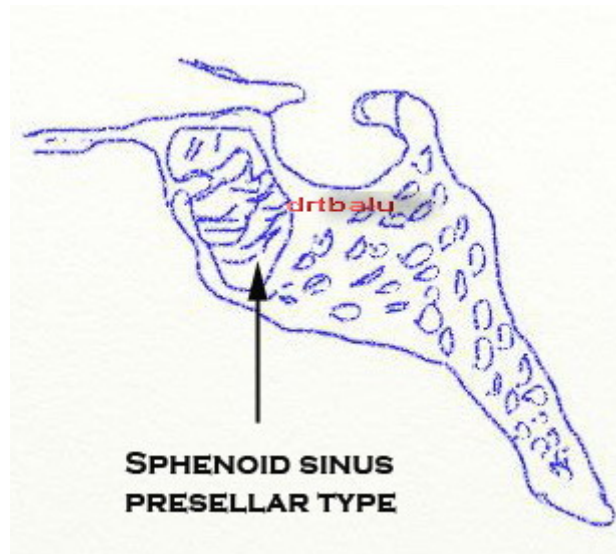
Conchal type:

In this type the area below the sella is a solid block of bone without an air cavity. This type is common in children under the age of 12 because pneumatization begins only after the age of 12.



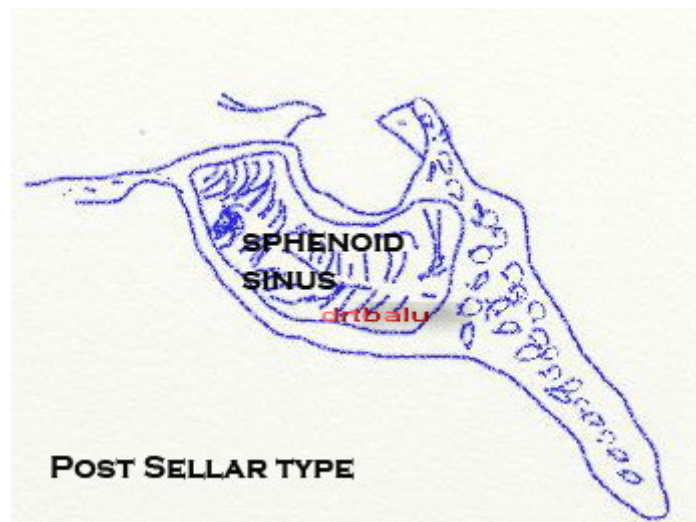
Presellar type:

In this type the air cavity does not penetrate beyond the coronal plane defined by the anterior sellar wall.



Sellar type:

In this type the air cavity extends into the body of the sphenoid below the sella and may extend as far posteriorly as the clivus. This type is commonly seen in 85% of individuals.



In well pneumatized sphenoid sinus, the pterygoid canal and a segment of maxillary division of trigeminal nerve could be identified in the lateral recess of the sphenoid sinus.

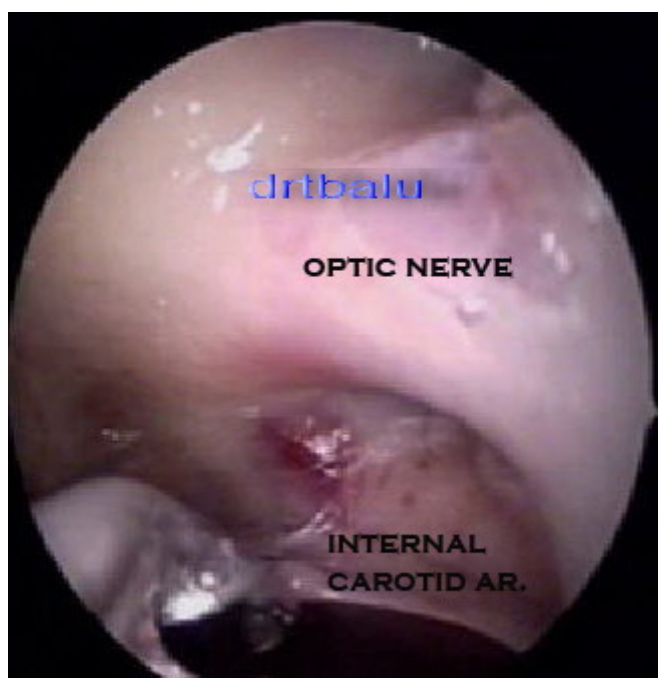The roof of the sphenoid (planum sphenoidale) anteriorly is continuous with the roof of ethmoidal sinus. At the junction of the roof and posterior wall of sphenoid the bone is thickened to form the tuberculum sella. Inferior to the tuberculum sella on the posterior wall is the sella turcica. It forms a bulge in the midline. The bone over the sella could be 0.5 - 1 mm thick. This may get thinner inferiorly. It is hence easy to breach the sella in this thinnest part. This area can be easily identified by a bluish tinge of the dura which is visible through the thin bony covering.

Possible variations of intersinus septum are as follows:

1. A single midline intersinus septum extending on to the anterior wall of sella.
2. Multiple incomplete septae may be seen
3. Accessory septa may be present. These could be seen terminating on to the carotid canal or optic nerve.

Lateral wall of sphenoid sinus: is related to the cavernous sinus. This sinus is formed by splitting of the dura. It extends from the orbital apex to the posterior clinoid process. Cavernous sinus contains very delicate venous channels, cavernous part of internal carotid artery, 3rd, 4th and 6th cranial nerves. It also contains some amount of fatty tissue.

The prominence of internal carotid artery is the postero lateral aspect of the lateral wall of sphenoid sinus. This prominence can be well identified in pneumatized sphenoid bones. On the antero superior aspect of the lateral wall of sphenoid sinus is seen the bulge formed by the underlying optic nerve. These two prominences are separated by a small dimple known as the opticocarotid recess. The optic nerve and internal carotid artery is separated from the sphenoid sinus by a very thin piece of bone. Bone dehiscence is also common in this area.



Endoscopic view of interior of sphenoid sinus

Histology:

All these sinuses are lined by respiratory type pseudo stratified ciliated columnar epithelium. This epithelium is composed of 4 major types of cells:

1. Ciliated columnar cells
2. Nonciliated columnar cells
3. Goblet cells
4. Basal cells

Since the mucosa lining the paranasal sinuses are attached to the bone it is known as mucoperiosteum. The mucoperiosteal lining of the sinus is thinner than the mucosal lining of the nasal cavity. This lining is continuous with the mucosal lining of the nasal cavity via the sinus ostium⁶. The ostium is though which various sinus cavities communicate with the nasal cavity. The concept of muciliary clearance mechanism pushing the secretions out via the natural ostium is the concept behind functional endoscopic sinus surgery.

References:

1. [Article in German] Feldmann H. HNO-Klinik, Universität Münster. Laryngorhinootologie. 1998 Oct;77(10):587-95.
2. Leonardo da Vinci. 1977. Anatomical drawings from the Royal Collection. London: Royal Academy of Arts. P 50.
3. Blanton PL, Biggs NL (1969) Eighteen hundred years of controversy: the paranasal sinuses. Am J Anat 124(2):135– 47
4. Stammberger H (1989) History of rhinology: anatomy of the paranasal sinuses. Rhinology 27(3):197–210.
5. Bolger WE, Anatomy of the Paranasal Sinuses. In: Kennedy DW, Bolger WE, Zinreich J (2001) Diseases of the sinuses, Diagnosis and management. B.C. Decker.
6. Graney DO, Rice DH, Paranasal sinuses anatomy. In: Cummings CW, Fredrickson JM, Harker LA et al (1998) Otolaryngology Head and Neck Surgery. Mosby, 3rd edn.
7. Van Cauwenberge P, Sys L, De Belder T et al (2004) Anatomy and physiology of the nose and the paranasal sinuses. Immunol Allergy Clin North Am 24(1):1–17.
8. Stammberger HR, Kennedy DW (1995) Paranasal sinuses: anatomic terminology and nomenclature. The Anatomic Terminology Group. Ann Otol Rhinol Laryngol Suppl Oct;167:7–16
9. Polavaram R, Devaiah AK, Sakai O et al (2004) Anatomic variants and pearls-functional endoscopic sinus surgery. Otolaryngol Clin North Am 37(2):221–42.
10. Joe JK, Ho SY, Yanagisawa E (2000) Documentation of variations in sinonasal anatomy by intraoperative nasal endoscopy. Laryngoscope 110(2):229–35.
11. Polavaram R, Devaiah AK, Sakai O et al (2004) Anatomic variants and pearls-functional

- endoscopic sinus surgery. *Otolaryngol Clin North Am* 37(2):221–42.
12. Kantarci M, Karasen RM, Alper F et al (2004) Remarkable anatomic variations in paranasal sinus region and their clinical importance. *Eur J Radiol* 50(3):296–302.